



Ethanol Ablation for Odontogenic myxoma: A case report of a new conservative treatment alternative

Journal:	<i>International Journal of Interdisciplinary Dentistry</i>
Manuscript ID	REVISTA-2021-0061.R1
Manuscript Type:	Clinical Reports
Date Submitted by the Author:	07-Apr-2022
Complete List of Authors:	Fariña, Rodrigo; Hospital Del Salvador; Universidad de Chile, Cirugía y Traumatología Bucal y Máxilo Facial Nuñez, Lorena; Universidad de Chile Facultad de Odontología, Andreo, Matias; Hospital Carlos Van Buren Deramond, Juan Pablo; Universidad de los Andes Facultad de Odontología
Keywords:	Ethanol, Ablation Techniques, myxoma

SCHOLARONE™
Manuscripts

Abstract:

Odontogenic myxoma is a maxillofacial tumor that is benign in nature. It is characterized by a slow-growing, painless, and site-aggressive behavior. A main feature is that it is not encapsulated so it has high potential of invasiveness and penetration into peripheral tissues. Large lesions may cause extensive compromise of the region.

Treatment strategy for Odontogenic Myxoma is still controversial. Radical resection with an appropriate surgical margin is recommended, but emerging evidence has suggested that a more conservative approach will result in less morbidity and adequate results.

This report shows a remarkable result on a 16-year-old patient who had a Mandibular Odontogenic Myxoma treated with a conservative approach. Intralesional absolute alcohol irrigation was performed during a 5-month period. Considerable volume reduction of the lesion happened which allowed a minimal overall resection. No recurrence was found after a 3 year follow-up.

Keywords: Ethanol, Ablation Techniques, myxoma

Ethanol Ablation for Odontogenic myxoma: A case report of a new conservative treatment alternative.

Introduction

Odontogenic myxoma is an uncommon maxillofacial tumor that is benign in nature. It is characterized by a slow-growing, painless, and site-aggressive behavior. A main feature is that it is not encapsulated so it has high potential of invasiveness and penetration into peripheral tissues. Large lesions may cause extensive compromise of the region. Tooth dislodgement with cortical bone expansion may be present, and in some more severe cases it can cause facial asymmetry. This odontogenic neoplasm originates from mesenchyme or odontogenic ectomesenchyme. Histologically is characterized by stellate and spindle-shaped cells dispersed in an abundant myxoid extracellular matrix^(1, 2). It is the third most frequent odontogenic tumor, with a reported incidence of approximately 0.07 cases per million people per year. It affects patients between the second and fourth decade of life. Females are affected predominantly in the ratio 2:1. Mandible is where they are most commonly found ^(1, 3). Clinically, it exhibits a slow growing pattern, with local bone destruction, cortical bone expansion, soft tissue infiltration, root resorption, and tooth malposition. Computed tomography is necessary for diagnosis and surgical treatment planning ⁽³⁾. Imaging demonstrates a unilocular or multilocular radiolucency, sometimes showing a fine “soap-bubble” or “honeycomb appearance”, occasionally with fine straight tennis racket trabeculations, with or without clearly defined borders. Differential diagnosis should include ameloblastoma, dentigerous cyst, odontogenic keratocyst, intraosseous

2

1
2
3 hemangioma, aneurysmal bone cyst and central giant cell granuloma ^(1, 3). It has a
4
5 recurrence rate from 10% to 43% with a mean of 25%. This high recurrence is
6
7 attributed to its myxomatous nature, lack of a capsule, and the penetration of the
8
9 lesion into the surrounding tissue. This feature makes effective curettage difficult ^{(1,}
10
11
12 2). Treatment for OM is mainly surgical. Most of cases in literature are treated with
13
14 surgical resection with recurrence rates between 6 - 13%. Another option
15
16 described was enucleation and curettage, with higher recurrence rates from 19% to
17
18 25%^(2, 3). To prevent recurrence, many authors recommend resection with 1 cm
19
20 linear bony margins⁽⁴⁾. Aggressive resection has the disadvantage of functional and
21
22 aesthetic deterioration and morbidity in donor site ⁽²⁾. **By the other side,**
23
24 **conservative treatment for young patients can be considered as an alternative to**
25
26 **avoid resection morbidity⁽⁵⁾.**

27
28
29
30
31 In this case report we present an alternative therapy by ethanol ablation. This
32
33 technique consists in injections of pure alcohol into the tumor's body to induce
34
35 dehydration, denaturation, and necrosis of tumor's cells accompanied by small
36
37 vessel thrombosis. This leads to tumor ischemia and destruction ⁽⁶⁾. The purpose of
38
39 this study is to report a new conservative treatment for mandibular odontogenic
40
41 myxoma with adequate results.

42 43 44 45 **Case Report**

46
47
48 A 16-year-old female patient **with no medical history**, was referred to the author's
49
50 private office for evaluation because of an **imaging** finding of an asymptomatic
51
52 mandibular tumor. Dental Cone Beam CT of the mandible showed extensive
53
54
55

1
2
3 radiolucent and multilocular area with blurred borders that extended from the
4
5 mandibular left body to the ipsilateral ramus with a “soap bubble” appearance (Fig
6
7 1). Biopsy was taken and histopathological results revealed a proliferation of
8
9 stellate and spindle cells in loose myxoid stroma, with no atypias or mitosis
10
11 observed, confirming odontogenic myxoma. The patient was given all treatment
12
13 modalities: conservative enucleation and curettage with coagulants (or block
14
15 resection and hemimandibulectomy. The initially proposed adjuvants were
16
17 Carnoy's Solution and liquid nitrogen. The patient's parents asked about the
18
19 possibility of using an adjuvant that would help reduce the size of the lesion and
20
21 would have a lower neurotoxic risk. A search for alternative treatments was carried
22
23 out, finding absolute alcohol ablation of bone lesions in the scientific literature.
24
25 However, as its use was not reported in odontogenic myxoma, it was decided to
26
27 stop its use if there was no change in the size of the lesion in a period of 5 months.
28
29 Finally, the patient decided a conservative treatment by intra-lesional ethanol
30
31 ablation. Informed consent was signed. A 5 mm gauge silastic cannula was
32
33 installed in the osteolytic expansive lesion as a drainage tube. Intralesional
34
35 irrigation through the cannula was performed under local anaesthesia (Lidocaine
36
37 2% 1:100.000 epinephrine). The lesion was treated with 3 ml of sterile 98 %
38
39 ethanol followed by profuse saline solution irrigation of the pathologic cavity. Intra-
40
41 lesional rinses were done two times a week (every 3 or 4 days), for a period of five
42
43 months without any complications (Fig 2). As there is no specific protocol for this
44
45 type of lesion using absolute alcohol, these rinses were performed long enough to
46
47
48
49
50
51
52
53
54
55
56
57
58
59
60

1
2
3 ensure a reduction in the size of the lesion and to obtain an objective measurement
4
5 by observing changes in radiographic radiopacity.
6
7

8 Management of the remaining lesion was performed by surgical curettage and
9
10 chemical treatment of the lesion with both Carnoy's solution and liquid nitrogen.
11
12 Ipsilateral Coronoidectomy was done under general anesthesia to decrease local
13
14 masticatory loads. A three-year follow – up was done. No recurrence of the lesion
15
16 was present (Fig 3).
17
18
19
20
21
22
23
24
25

26 **Discussion**

27
28
29 Odontogenic Myxoma have a high recurrence rate and it is attributed to its nature,
30
31 lack of a capsule, and the penetration of the lesion into the surrounding tissue. This
32
33 features makes conservative treatment by curettage ineffective, so resection is the
34
35 preferred treatment modality. M. Saalim et al reported in their systematic review
36
37 the overall recurrence rate of odontogenic mixoma. He published that OM
38
39 recurrence was 13% during a mean follow up period of 10 years. With conservative
40
41 treatment the recurrence rate was 19% (mean follow up 11 years) and after
42
43 resection it was 6% (mean follow up nine years)⁽²⁾.
44
45
46
47

48 A search in PUBMED was conducted to assess whether there was literature about
49
50 de use of alcohol for the treatment of these lesions using the following searching
51
52 strategy (((odontogenic myxoma[Title]) OR odontogenic myxoma[Abstract])) AND
53
54
55

1
2
3 ((alcohol[Abstract]) OR alcohol[Title]) & (((odontogenic myxoma[Title]) OR
4 odontogenic myxoma[Abstract])) AND ((Alcohols[MeSH Terms]) OR Ethanol[MeSH
5 Terms]) " finding no publications about this modality. However there are reports of
6 its use in other types of bone and extra-bone lesions, with a reduction of their initial
7 volumes and in some cases total remission (Table 1) ^(6,8,11,13) **Bening tumors and**
8 **metastatic bone lesions can be managed by ablation techniques.** These treatment
9 modalities include ethanol or acetic acid injection, thermal ablation by laser,
10 radiofrequency, microwave, cryoablation and radiofrequency ionization ⁽²⁾. Ethanol
11 **injection** produces coagulative necrosis of targeted tissue due to cell dehydration
12 and protein denaturation. Also induces ischemic necrosis due to small blood vessel
13 thrombus formation and inhibition of enzymatic activity in surrounding tissues
14 which result in local fibrosis and tissue atrophy ⁽⁷⁾ . Reported experience with
15 ethanol ablation has focused mainly on therapy for hepatocelular carcinoma ^(8, 9).
16 Likewise, there are studies that show excellent results with ethanol injection for the
17 treatment of giant cell tumors, osteoid osteomas, skeletal metastasis, and other
18 bone lesions ⁽⁹⁻¹¹⁾. In this case report we present an unconventional conservative
19 management **for a** mandibular odontogenic myxoma by recurrent **continuous** intra-
20 lesional "absolute alcohol" **rinses that** were performed **through a cannula.**
21 Regarding the alcohol volume used, it is reported that it depends on the size of the
22 lesion to be treated ^(2,9).

23
24
25
26
27
28
29
30
31
32
33
34
35
36
37
38
39
40
41
42
43
44
45
46
47
48
49
50 **Regarding the decompression of mandibular keratocysts, it is indicated that 6-12**
51 **months after decompression is considered a period in which there is sufficient**
52 **bone formation to perform enucleation. Even at 3 months there is a decrease in the**
53
54
55

1
2
3 volume of these lesions by 55%, increasing bone density by 46%⁽¹²⁾. Taking as
4
5 reference the times in the treatment in keratocysts, a CT control was performed at
6
7 5 months, observing a significant decrease in the size of the lesion, surgical
8
9 treatment of the remaining odontogenic myxoma was performed.
10
11

12
13 The disadvantage of this technique is the unpredictable alcohol diffusion, but
14
15 several published studies report excellent results concerning safety and efficacy in
16
17 bone and soft tissue lesions ^(9, 13). This approach was chosen to avoid functional
18
19 and aesthetic disadvantages associated to resective treatment. Considerable
20
21 reduction of the lesion's volume was achieved which allowed a "minimal overall
22
23 resection" and in a final stage the remaining lesion was managed with surgical
24
25 curettage and chemical treatment by the combination of Carnoy's solution and
26
27 cryoablation with liquid nitrogen as local adjuvant applied locally to induce tissue
28
29 ischemia and trigger protein denaturation with cell membrane breakdown, with
30
31 remarkable results. This outcome is similar as described in literature where positive
32
33 response is demonstrated when using high concentration alcohol injections
34
35 associated with aggressive curettage of the lesions ^(6, 8, 11, 14). It is outlined that
36
37 Carnoy's solution is effective as coadjuvant treatment for odontogenic myxoma ⁽⁵⁾
38
39 but in our case it was discarded in the initial stages due to the neurotoxic
40
41 properties of this solution and its possible damage to the inferior alveolar nerve⁽¹⁵⁾.
42
43
44
45
46
47

48 In this case the conservative approach was an effective therapy and no recurrence
49
50 was found after a 3 year follow-up, however the patient should be monitored once
51
52 a year.
53
54
55

Conclusion

There are no reports in the literature about the use of alcohol as a chemoablative agent for the treatment of odontogenic myxoma. This study reveals a conservative treatment with no signs of recurrence after a three-year follow-up. Additionally, high concentration ethanol is a low-cost and relatively safe treatment alternative. Thus, it is proposed that this treatment modality may be helpful in similar cases, however more studies are needed to prove it's long term efficacy.

Informed Consent

Written informed consent was obtained.

FIGURE 1. Odontogenic myxoma. Dental Cone Beam CT of the mandible showed extensive radiolucent and multilocular area with imprecise borders that extended from the mandibular left body, to the ipsilateral ramus with a “soap bubble” appearance

FIGURE 2. Control five months after washing with absolute alcohol

FIGURE 3. Control three years post ethanol Ablation and Enucleation of mandibular Myxoma

TABLE 1. Bone lesions can be treated by different ablation techniques

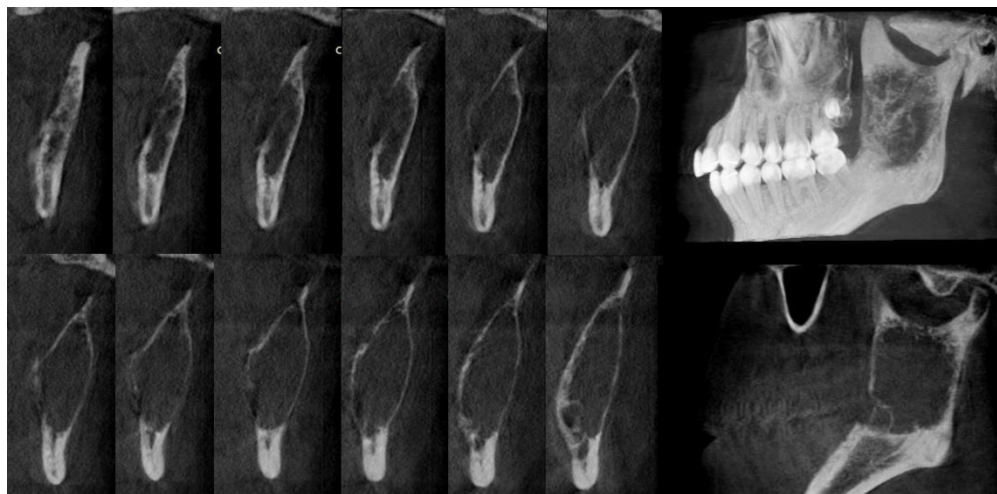
References

1. Adel K. El-Naggar JKCC, Jennifer R. Grandis, Takashi Takata, Pieter J. Slootweg. WHO classification of Head and Neck Tumours. In: Grandis, JR TT, Slootweg P, editors. WHO classification of Head and Neck Tumours. 4th edition ed. Lyon2017. p. 229-30.
2. Saalim M, Sansare K, Karjodkar FR, Farman AG, Goyal SN, Sharma SR. Recurrence rate of odontogenic myxoma after different treatments: a systematic review. *Br J Oral Maxillofac Surg*. 2019;57(10):985-91.
3. Dotta JH, Miotto LN, Spin-Neto R, Ferrisse TM. Odontogenic Myxoma: Systematic review and bias analysis. *Eur J Clin Invest*. 2020;50(4):e13214.
4. Ringer E, Kolokythas A. Bone Margin Analysis for Benign Odontogenic Tumors. *Oral Maxillofac Surg Clin North Am*. 2017;29(3):293-300.
5. Martins H, Vieira E, Gondim A, Osório-Júnior H, Da Silva J, Da Silveira É. Odontogenic Myxoma: Follow-Up of 13 cases after conservative surgical treatment and review of the literature. *Journal of Clinical and Experimental Dentistry*. 2021:0-.
6. Swierz MJ, Storman D, Riemsma RP, Wolff R, Mitus JW, Pedziwiatr M, et al. Percutaneous ethanol injection for liver metastases. *Cochrane Database Syst Rev*. 2020;2(2):Cd008717.
7. Hahn SY, Shin JH, Na DG, Ha EJ, Ahn HS, Lim HK, et al. Ethanol Ablation of the Thyroid Nodules: 2018 Consensus Statement by the Korean Society of Thyroid Radiology. *Korean J Radiol*. 2019;20(4):609-20.
8. Morhard R, Nief C, Barrero Castedo C, Hu F, Madonna M, Mueller JL, et al. Development of enhanced ethanol ablation as an alternative to surgery in treatment of superficial solid tumors. *Scientific Reports*. 2017;7(1):8750.
9. Filippiadis DK, Tutton S, Kelekis A. Percutaneous bone lesion ablation. *Radiol Med*. 2014;119(7):462-9.
10. Lee MJ, Mueller PR, Dawson SL, Gazelle SG, Hahn PF, Goldberg MA, et al. Percutaneous ethanol injection for the treatment of hepatic tumors: indications, mechanism of action, technique, and efficacy. *AJR Am J Roentgenol*. 1995;164(1):215-20.
11. Solooki S, Keikha Y, Vosoughi AR. Can ethanol be used as an adjuvant to extended curettage in order to reduce the recurrence rate of aneurysmal bone cyst? *Rev Bras Ortop*. 2017;52(3):349-53.
12. Zhao Y, Liu B, Han QB, Wang SP, Wang YN. Changes in bone density and cyst volume after marsupialization of mandibular odontogenic keratocysts (keratocystic odontogenic tumors). *J Oral Maxillofac Surg*. 2011;69(5):1361-6.
13. Ulici A, Florea DC, Carp M, Ladaru A, Tevanov I. Treatment of the aneurysmal bone cyst by percutaneous intracystic sclerotherapy using ethanol ninety five percent in children. *Int Orthop*. 2018;42(6):1413-9.
14. Jones KB, DeYoung BR, Morcuende JA, Buckwalter JA. Ethanol as a local adjuvant for giant cell tumor of bone. *Iowa Orthop J*. 2006;26:69-76.

1
2
3
4
5
6
7
8
9
10
11
12
13
14
15
16
17
18
19
20
21
22
23
24
25
26
27
28
29
30
31
32
33
34
35
36
37
38
39
40
41
42
43
44
45
46
47
48
49
50
51
52
53
54
55
56
57
58
59
60

15. Ribeiro Junior O, Borba AM, Alves CA, de Gouveia MM, Coracin FL, Guimaraes Junior J. Keratocystic odontogenic tumors and Carnoy's solution: results and complications assessment. Oral Dis. 2012;18(6):548-57.

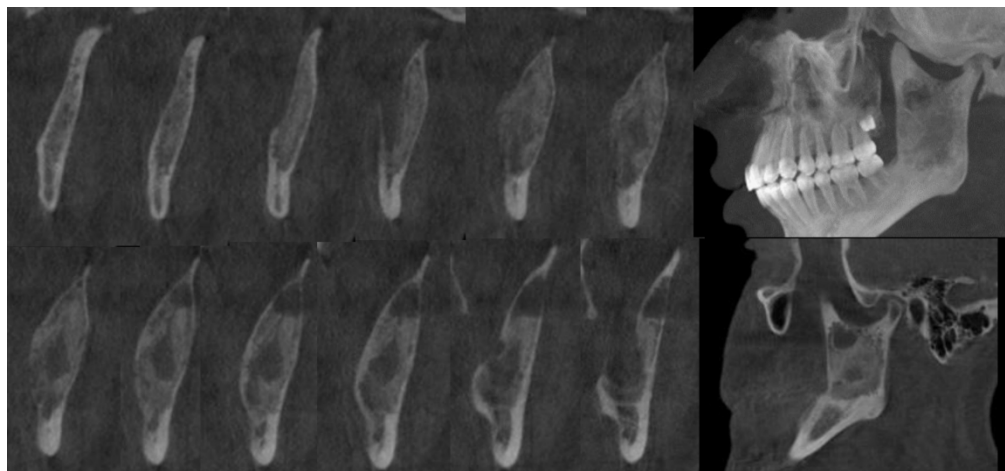
For Review Only



Odontogenic myxoma. Dental Cone Beam CT of the mandible showed extensive radiolucent and multilocular area with imprecise borders that extended from the mandibular left body, to the ipsilateral ramus with a "soap bubble" appearance

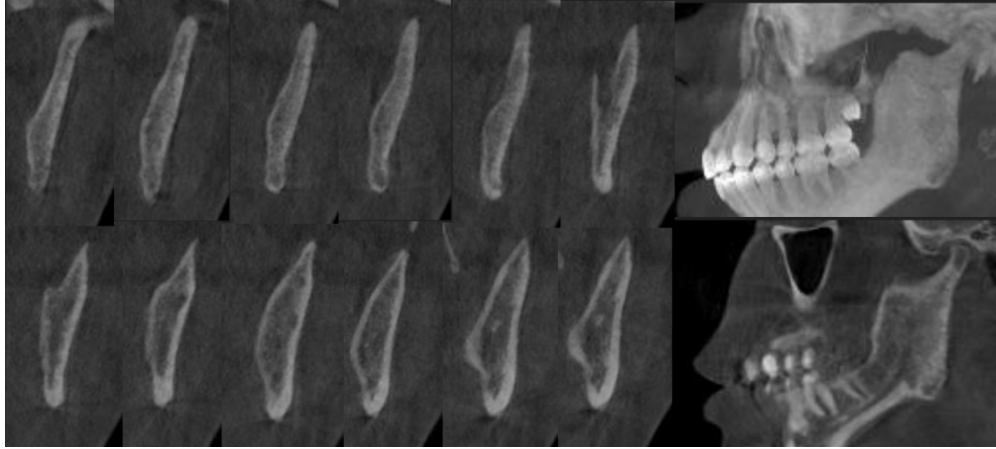
975x478mm (96 x 96 DPI)

1
2
3
4
5
6
7
8
9
10
11
12
13
14
15
16
17
18
19
20
21
22
23
24
25
26
27
28
29
30
31
32
33
34
35
36
37
38
39
40
41
42
43
44
45
46
47
48
49
50
51
52
53
54
55
56
57
58
59
60



Control five months after washing with absolute alcohol

796x372mm (96 x 96 DPI)



Control three years post ethanol Ablation and Enucleation of mandibular Myxoma

848x379mm (96 x 96 DPI)

Table 1

Type of lesion treated	Autor	Year	Study type	Location	Results
Liver metastases from colorectal carcinoma or other extrahepatic primary cancers	Swierz MJ, Storman D, Riesma RP, Wolff R, Mitus JW, Pedziwiatr M, Kleijnen J, Bala MM ^{5,7,10,11}	2020	Cochrane Review	Liver	66,2% of the lesions shrunk at least 25% of its volume, by the Percutaneous Etanol Injection and Transcatheter Arterial Chemoembolisation treatment.
Squamous Cell Carcinoma	Morhard R, Nief C, Barrero Castedo C, Hu F, Madonna M, Mueller J, Dewhirst M, Katz D, Ramanujam N ^{5,7,10,11}	2017	Estudio en animales	Hamster Cheek Pouch	Pure etanol: The tumor volumen decreased in a mean of 32+- 34% (mean +- s.d.) from the initial volume at day 7. Of the 12 tumors ablated, 4 had complete regression at day 7.
Primary and secondary Aneurismal Bone cyst (ABC)	Solooki S, Keikha Y, Reza Vosoughi A ^{5,7,10,11}	2016	Descriptive study	Bone Limbs	Primary ABC: 6.9% had recurrence with alcohol (etanol 96%) and curettage & electrocauterization. Secondary ABC: 4,5% had recurrence with alcohol (etanol 96%) and curettage & electrocauterization.
Giant Cell Tumor	Jones K, DeYoung B, Morcuende J, Buckwalter J ^{5,7,10,11}	2006	Descriptive study	Bone	Five recurrences of 25 GIANT CELL TUMOR present without prior treatment and 1 recurrence of 6 GIANT CELL TUMORS present recurrent after prior treatment