Revista Clínica de Periodoncia, Implantología y Rehabilitación Oral

Rehabilitation of a patient diagnosed with Ectodermal Dysplasia presenting hypodontia: a case report

Journal:	*International Journal of Interdisciplinary Dentistry*
Manuscript ID	Draft
Manuscript Type:	Clinical Reports
Date Submitted by the Author:	n/a
Complete List of Authors:	Machado, Mariela; The University of Sydney Klineberg, Iven ; The University of Sydney Santos, Pamela; Centro Universitario de Araraquara, Ficho, Ana Carolina; Centro Universitario de Araraquara Marcantonio, Claudio; Centro Universitario de Araraquara Margonar, Rogério; Centro Universitario de Araraquara
Keywords:	Dental Implants, Ectodermal Dysplasia, Bone graft

SCHOLARONE™
Manuscripts

BORRADOR

Rehabilitation of a patient diagnosed with Ectodermal Dysplasia presenting hypodontia: a case report

Running Title: Rehabilitation patient with Ectodermal Dysplasia

Abstract

Purpose: The study showed a patient with Ectodermal Dysplasia (ED) who was treated with implants and fixed dental prosthesis by a multidisciplinary team. *Case Report:* Acrylic resin dental prostheses were designed as long-term provisionals, which allowed modifications when required. After imaging and treatment planning, four implants were placed in the inter-foramenal area of the mandible and 2 years later the definitive prosthesis was fitted. In a second phase, the patient received a combination of autogenous and allogeneic bone grafts in the maxilla. The autogenous graft was removed from the retro-molar region in the mandible. He also received a fixed dental prosthesis supported by 4 implants on the position of the upper canines and second pre-molars. *Conclusion:* Patient reports successful outcomes and despite the long treatment, patient states is confident with his appearance and speaking improvement. Follow-up was done every six months, for 10 years, and showed encouraging post-treatment outcomes.

Key-words: Dental Implants; Ectodermal Dysplasia; Bone graft

Clinical Relevance

Ectodermal Dysplasia (ED) is a group of disorders characterised by abnormalities of ectodermal-derived tissues, such as skin, hair, nails, teeth and sweat glands. ED can be particularly challenging for oral health professionals due to the lack of in-depth knowledge and training. This case report is of a patient diagnosed with ED who was treated with dental implants and fixed dental prosthesis by a multidisciplinary team.

For Review Only
BORRADOR

Introduction

Ectodermal Dysplasia (ED) is an inherent disorder that is characterised by abnormalities of ectodermal-derived tissues, such as skin, hair, nails, teeth and sweat glands [1-2]. Clinically, ED may be identified by the following classic features: hypodontia (missing teeth), hypohydrosis (abnormal sweat glands), hypotrichosis (abnormal hair) and dysmorphic facial features[3]. ED is a rare condition which is particularly challenging for oral health professionals as the dental management is often complex. Patients should be encouraged to look for a comprehensive care program that can work in cooperation with patient organisations and also may work as a treatment-planning checklist for professionals and patients[4].

A comprehensive oral examination should be performed as part of the initial assessment to better understand the clinical manifestations of ED. Oral manifestations include anodontia or oligodontia, enamel hypoplasia, reduced or asymmetric alveolar ridge height, maxillary retrusion and high palatal arch. Other oral-craniofacial concerns include abnormal patterns of tooth eruption, numerical variations, poorly shaped or widely spaced teeth, defects in the mineralised tissues and salivary hypofunction. In addition, remaining teeth tend to have reduced width in children, and some level of attrition and root reabsorption may be seen in the primary dentition. The resulting lack of bone formation and the abnormal oral and craniofacial development lead to significant diagnostic and treatment challenges[1, 5].

A long-term treatment plan might be established at the age of 8-10 years, followed by further treatment details for the following years. Dental rehabilitation with dental implants and removable or fixed dental prostheses are possible treatments[4,5]. In a study using micro-computed tomography, authors have evaluated the quality of bone in implant sites in patients with ED, and reported that patients' bones had a more compact, dense and well-connected structure when compared to the non-disorder control group[6]. This outcome indicates that it is possible to successfully load implants placed in patients with ED.

For Review Only
BORRADOR

The present study is a case report of an ED patient treated with dental implants and fixed dental prostheses with a multidisciplinary approach.

Case Report

A 16-years-old male patient, diagnosed with ED by his paediatrician, attended a private clinic in Araraquara, Brazil seeking treatment for teeth replacement. The patient presented with only two anterior teeth present, sparse hair, dry skin, severe hypodontia, and moderate dysphonia. No sign of abnormal sweating was noted and there was no family history of ED (Figure 1). An initial assessment was performed and a long-term treatment plan was developed. A detailed written and consent form were discussed and accepted.

Clinical and radiographic examinations included Orthopantomogram (OPG) assessment of maxillary and mandibular bone to determine the possibility of implant placement (Figure 2 and 3). Acrylic dental prostheses were to be used as long-term provisional treatment prostheses, which could be modified as required.

As agreed with the overall treatment sequencing, careful initial planning indicated dental implants were to be placed when the patient was 19 years old. At that time, regular platform (external hex) dental implants of 3.75mm diameter, and lengths of 10mm and 11.5mm were placed in the inter-foramenal region of the anterior mandible .

The lower metalloplastic prosthesis was placed when the patient was 21 years old.

In order to gain bone volume in the maxilla, a combination of autogenous and allogeneic bone grafts procedure was performed under local anaesthesia. The autogenous graft was removed from the retromolar region of the mandible and placed bilaterally between the maxillary first molars and the existing maxillary incisors.

No tooth extraction was needed and the two maxillary incisors were re-contoured with metal ceramic crowns, following to the diagnostic wax-up developed as part of the treatment

BORRADOR
For Review Only

planning. Four dental implants were placed in the maxilla -two 3.5 x10mm implants in quadrant 2, and in quadrant 1, one 3.75 x10mm and one 3.75 x 11.5mm (Conexão Sistemas de Prótese Ltda). The dental implant positions selected corresponded to maxillary canines and second pre-molars. (Figure 4 and 5)

This patient reported that he was satisfied with the outcomes. Despite the long treatment time, he confirmed that he was happy with his appearance and was confident with his ability to communicate and interact socially. A follow-up of soft and hard tissues as well and function and aesthetics was done every six months for 10 years (Figure 6).

Discussion

Ectodermal Dysplasia manifestations appear to be invariably of genetic aetiology, with a high number of possible presentations encountered among the syndromes, with a broad variety of clinical expressions. The actual number of genes that can cause ED is not known. Many of the conditions can be manifested by only one or a few family members and there is a significant clinical overlap among the conditions. As genetic tests are not easily available, diagnosis is made primarily by clinical characteristics[4].

Individuals affected may have a combination of clinical signs such as brittle or abnormally developed nails, sparse, fine or coarse curly hair, deficiency of sweat glands, skin problems (soft, thin and dry, easily prone to eczema), frontal bone bossing, prominent lips, depressed midface and nasal bridge, dental malformations and dysphagia, in addition to possible vision and hearing complications[3,7].

Oral and dental symptoms vary from subtle to well recognisable when compared with normal features. It has also been described that a high percentage of patients with hypodontia are diagnosed with ED, and 70% to 80% of ED patients have some kind of oral-related problem, with hypodontia being the most common oral manifestation[5].

BORRADOR
For Review Only

The diagnosis of congenitally missing teeth is based on radiographic examination. A general recommendation from orthodontists is that if any incisor is missing at the age of 8, an orthopantomogram (OPG) should be taken to reveal any unerupted or congenitally missing teeth[8]. In our reported case, OPG was required to complete the treatment planning according to the clinical team's approach.

Authors have stated that early intervention offers children the opportunity to develop normal speech, chewing, swallowing, and facial support. Partial or complete removable dental prostheses may be considered from 2 or 3 years of age. When the child matures, removable dental prostheses need to be rebased due to jaw growth. In teenagers, orthodontic treatment is usually indicated to prepare the mouth for fixed rehabilitation and implant placement. Conventional prosthodontic treatment may include partial and complete removable dental prostheses (RDP), overdentures and fixed dental prostheses (FDP) are well documented in the treatment of ED patients[8]. In this report, the patient was treated with partial or total RDP before the placement of implants, although the patient was unable to wear them. Nonetheless, the patient only sort definitive and long-term treatment when he reached 19 years of age. The lack of teeth, bone and early diagnosis is likely to lead to challenging and long treatment.

Complete removable prostheses have low retention, while implant-supported prostheses have both functional and aesthetic aspects advantages[9]. Authors have suggested that dental implants are a valuable treatment for patients diagnosed with ED. An investigation of the survival rate of dental implants in ED patients (median age of 25 years) evaluated 78 implants placed in 8 patients. Seven patients underwent grafting procedures before implant placement and one implant was lost[10]. In our study, due to the narrow bone width, a major bone graft procedure was performed to allow further dental implants placement.

Ideally, restorations/prostheses should be in place before the child starts school. The principal aims of dental treatment in these children are to restore missing bone and teeth, establish an acceptable occlusal vertical dimension, and provide support for facial soft tissues

BORRADOR
For Review Only

and improve aesthetics and function. Moreover, it is important to consider the definitive outcomes of prosthodontic rehabilitation in the early stages of therapy, including temporary prosthodontic solutions[4]. The primary area of concern is the early consideration of definitive therapy for the optimal placement of the dental implants and the provision of temporary prosthodontic treatments that will meet the aesthetic and functional needs of the patient during growth and development[5].

The literature is limited on the extraction of deciduous teeth in patients with tooth agenesis as it relates to treatment with dental implants. Authors have mentioned that in the clinical management of young individuals with hypodontia, deciduous teeth were extracted for different reasons during growth. Basically, every year in function is a bonus and the postponing of implant therapy will increase the possibilities of a positive future prognosis for dental implants and the patient's aesthetics. This strategy must be balanced against the risk of losing alveolar bone at future implant sites. If dental implant therapy is the treatment of choice, implant placement should ideally be done close to the extraction or exfoliation of the deciduous teeth to ensure the maximal preservation of alveolar bone[11]. However, in this case report, the patient had deciduous teeth extractions many years before the implants were placed. This procedure challenged the initial approach to treatment planning and following prosthodontics and surgery.

The Delphi Study Consensus Meeting reported answers for questions raised on the complex management in patients diagnosed with ED, presenting hypodontia and alveolar bone loss[8-13]. As mentioned in another study, fixed dental prostheses supported by implants in ED showed great improvements in aesthetics, chewing ability, diet and speech[13].

To evaluate the best age for implant placement, clinicians should consider the status of the skeletal growth, the degree of the hypodontia and the level of interference of possible psycho-social problems in the lives of the patients and their parents[8]. Some authors have described that, because of the impact of growth in the upper jaw, dental implants should be placed in the maxilla when finished growth is completed or when the bone is mature. However, in patients presenting with anodontia, dental implants in the anterior mandible must be considered, as growth in this

BORRADOR
For Review Only

area is often completed by 6 years of age[14]. Implants placed in girls aged 15 years and boys aged 18 years have more predictable outcomes. In growing children, the primary area of concern is the mandibular midline. These patients have to be monitored closely to avoid the implant-supported prosthesis disturbing growth[15]. Following this reasoning, the patient in our study received dental implants for the mandible when growth was completed. Prostheses were rebased during the treatment whenever required. The most recent follow-up was at 10 years, before the patient's relocation to another city.

A multidisciplinary group with professionals from different specialties: orthodontics, paediatric dentistry, oral and maxillofacial surgery and prosthodontics is ideally required. A range of documentations is needed which include radiographs, study models, details of clinical examination and medical history. The most important feature for these types of patient is early diagnosis and continuous coordination of the different steps in the preliminary therapy plan, respecting growth and development. Issues discussed among specialists include: family behavior, long-term treatment needs, aesthetics, preventive measures, pattern of facial growth, tooth features and development, orthodontic needs, dentoalveolar and jaw growth, possible overeruption of remaining teeth, extraction of primary teeth and replacement of missing teeth, space maintenance and analysis of quantity/quality of bone[5]. In our case report, the patient was managed with interdisciplinary collaboration led by a prosthodontist and an oral and maxillofacial surgeon.

Conclusion

A patient with Ectodermal Dysplasia treated with dental implants reported encouraging post-treatment outcomes, after prosthodontic rehabilitation, and follow-up of 10 years has confirmed improvements.

Legends of figures

Figure 1. Patient at initial assessment. Extra-oral pictures showing aspects of disorder.

BORRADOR
For Review Only

Figure 2. Clinical view of the patient (A: upper teeth and B: mandible).

Figure 3. Orthopantomogram (OPG) after bone graft (A).

Figure 4. Final prosthetic rehabilitation: occlusal view of the maxilla and the mandible (A and B); frontal view of upper and lower prostheses (C).

Figure 5. OPG after dental implant placements: four dental implants in the maxilla and four in the mandible, supporting fixed dental prostheses.

Figure 6. OPG after 10years of dental implant placements.

References

1. AlNuaimi R, Mansoor M. Prosthetic rehabilitation with fixed prosthesis of a 5-year-old child with Hypohidrotic Ectodermal Dysplasia and Oligodontia: a case report. J Med Case Rep. 2019;13(1):329.
2. Hasan S, Govind M, Sawai MA, Ansari MD. Hypohidrotic ectodermal dysplasia with autosomal recessive inheritance pattern: Report of a rare and unusual case with a brief review of literature. J Oral Maxillofac Pathol. 2019;23(3):479.
3. Gholman RR, Kassar WM, El Meligy OA. Dental Rehabilitation of a Child with Ectodermal Dysplasia: A Case Report. Int J Clin Pediatr Dent. 2019;12(4):362–5.
4. Liu Y, Tang C. Interdisciplinary treatment with implant-supported prostheses for an adolescent with ectodermal dysplasia: A clinical report. J Prosthet Dent. 2019; 1-6.
5. Bergendal B. Orodental manifestations in ectodermal dysplasia-a review. Am J Med Genet A. 2014;164a(10):2465-71.
6. Bergendal B, Bergendal T, Hallonsten AL, Koch G, Kurol J, Kvint S. A multidisciplinary approach to oral rehabilitation with osseointegrated implants in children and adolescents with multiple aplasia. Eur J Orthod. 1996;18(2):119-29.

BORRADOR
For Review Only

7. Silthampitag P, Klineberg I, Jones AS, Austin B, Zee KY, Wallace C, et al. Ultramicroscopy of bone at oral implant sites: a comparison of ED and control patients. Part 1-defining the protocol. Int J Prosthodont. 2011;24(2):147-54.
8. Hickey AJ, Vergo TJ, Jr. Prosthetic treatments for patients with ectodermal dysplasia. J Prosthet Dent. 2001;86(4):364-8.
9. Bergendal B. Prosthetic habilitation of a young patient with hypohidrotic ectodermal dysplasia and oligodontia: a case report of 20 years of treatment. Int J Prosthodont. 2001;14(5):471-9.
10. Klineberg I, Cameron A, Whittle T, Hobkirk J, Bergendal B, Maniere M, et al. Rehabilitation of children with ectodermal dysplasia. Part 1: An International Delphi Study. Int J Oral MaxIlofac Implants. 2013;28(4):1090–100.
11. Klineberg I, Cameron A, Hobkirk J, Bergendal B, Maniere MC, King N, et al. Rehabilitation of children with ectodermal dysplasia. Part 2: An International Consensus Meeting. Int J Oral Maxillofac Implants. 2013;28(4):1101-09.
12. Machado M, Wallace C, Austin B, et al. Rehabilitation of ectodermal dysplasia patients presenting with hypodontia: outcomes of implant rehabilitation part 1. J Prosthodont Res. 2018;62(4):473-8.
13. Kramer FJ, Baethge C, Tschernitschek H. Implants in children with ectodermal dysplasia: a case report and literature review. Clin Oral Implants Res. 2007;18(1):140-6.
14. Guckes AD, Scurria MS, King TS, McCarthy GR, Brahim JS. Prospective clinical trial of dental implants in persons with ectodermal dysplasia. J Prosthet Dent. 2002;88(1):21-5.
15. Cronin RJ, Jr., Oesterle LJ, Ranly DM. Mandibular implants and the growing patient. Int J Oral Maxillofac Implants. 1994;9(1):55-62.

For Review Only
BORRADOR

Figure 1. Patient at initial assessment. Extra-oral pictures showing aspects of disorder.

267x105mm (300 x 300 DPI)

BORRADOR

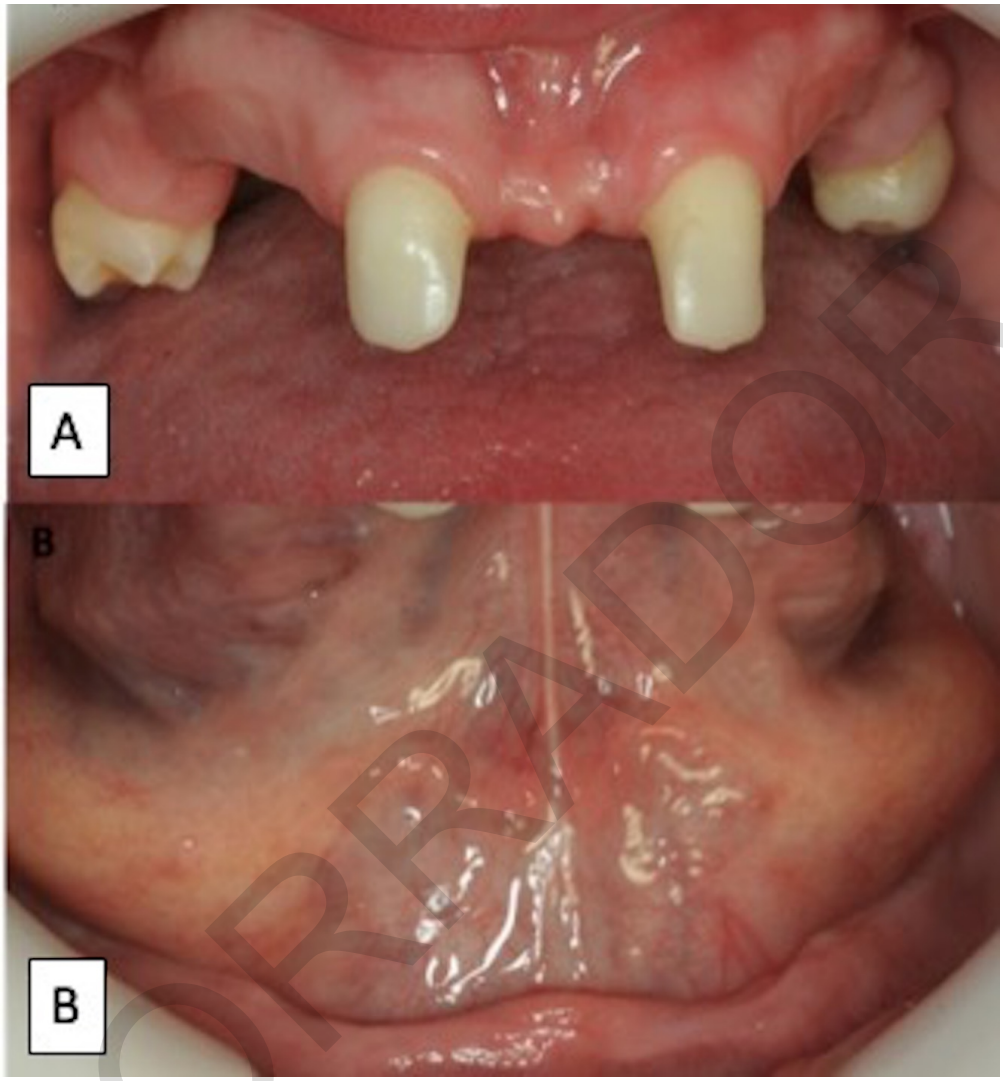

Figure 2. Clinical view of the patient (A: upper teeth and B: mandible).

112x120mm (300 x 300 DPI)

BORRADOR

Figure 3. Orthopantomogram (OPG) after bone graft (A).

117x59mm (300 x 300 DPI)

BORRADOR

Figure 4. Final prosthetic rehabilitation: occlusal view of the maxilla and the mandible (A and B); frontal view of upper and lower prostheses (C).

408x85mm (300 x 300 DPI)

BORRADOR

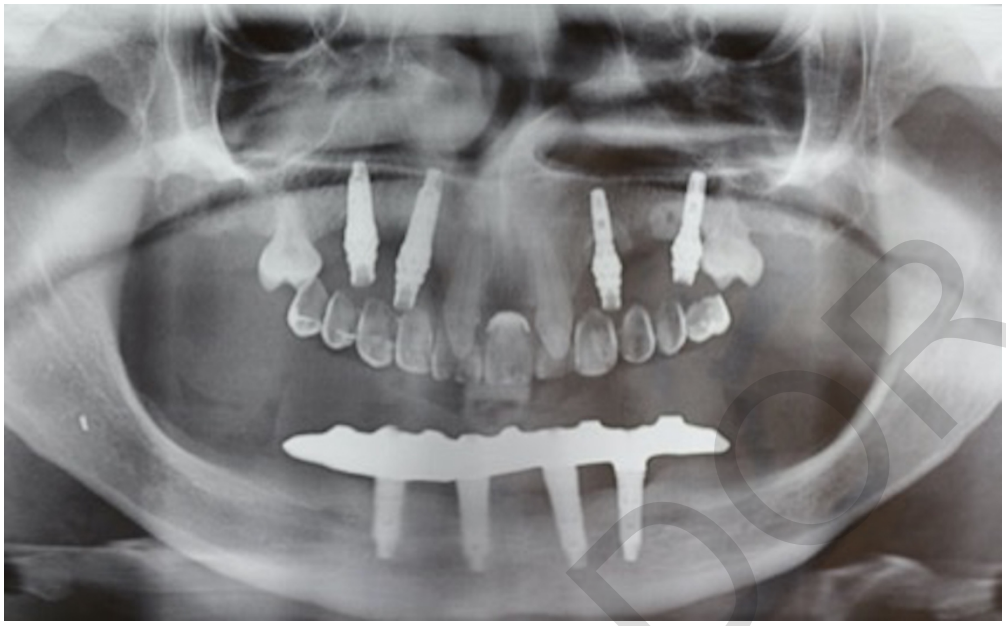

Figure 5. OPG after dental implant placements: four dental implants in the maxilla and four in the mandible, supporting fixed dental prostheses.

149x92mm (300 x 300 DPI)

BORRADOR

Figure 6. OPG after 10years of dental implant placements.

242x109mm (300 x 300 DPI)

BORRADOR